

PATIENT

Tiger Smith

SPECIES

Feline

BREED

DSH

SEX

Male

AGE

14 weeks

WEIGHT

6.13lbs

INTERPRETED BY

Maggie Machen Lamy,
DVM, DACVIM
(Cardiology)

IMAGING PERFORMED BY

Amy Mayhew, LVT

HOSPITAL NAME

SVS Imaging MI

REFERRING VET

Oxford Veterinary
Hospital

INVOICE

26607

DATE

9/28/22

PRESENTING CLINICAL SIGNS

History: Grade 4/6 heart murmur. Study performed under Isoflurane anesthesia.

ECHOCARDIOGRAM FINDINGS

2D, m-mode, color flow and doppler imaging is available. The left ventricular wall is mildly thickened for this body size. There is a mildly hyperechoic endocardium consistent with fibrosis. Mild papillary muscle remodeling. The right ventricle is normal. There is mild left atrial enlargement present. No right atrial enlargement present. Normal RVOT velocity. Abnormal anterior motion of the mitral valve is present on 2D imaging. Normal LVOT velocity and no turbulence seen on color flow. The anterior leaflet of the MV is mildly elongated and thickened with abnormal closure, consistent with dysplasia. No MR or TR. No other obvious valvular regurgitation is present. No obvious intra or extracardiac shunts seen. There is no pericardial effusion noted. No pleural effusion appreciated.

CARDIAC CHART

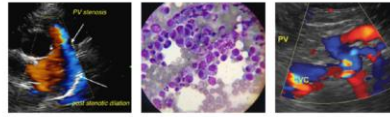
FELINE CARDIAC PARAMETERS	BODY WEIGHT (kg)	HR (BPM)	IVSd (cm) (Moise, Pipers)	LVIDd (cm) (Moise, Pipers)	LWVd (cm) (Moise, Pipers)	FS (%)	EF (%)
NORMAL PARAMETER	-----	150-240	0.35-0.55	<2 (mean 1.5)	3.5-0.55	35-67	80-100
PATIENT	2.8	NM	0.50	1.29	0.53	50	92
FELINE CARDIAC PARAMETERS	LA/AO (Boon)	LA/AO HEART BASE (Swe) (Abbott)	LA 2D short axis Base view (cm) (Abbott)		LVOT VEL (m/s)	RVOT VEL (m/s)	E max (m/s)
NORMAL	<1.5	<1.3	<1.2		<1.6	<1.3	<0.9
PATIENT	NM	1.6	1.35		1.5	0.7	NM

**Note: All measurements based upon multi-modal images and methods. An average value is reported.*
Adapted from June Boon, Veterinary Echocardiography, 1998
Abbott J & MacLean H JVIM 2006;20: 111-119, Moise et al. Am J Vet Res 47:1476, 1986. Pipers et al. Am J Vet Res 40:882, 1979.

INTERPRETATION OF THE FINDINGS & FURTHER RECOMMENDATIONS

The suspected diagnosis and cause of the murmur is mitral valve dysplasia leading to mild LV hypertrophy, mild LA enlargement and an obstructive LVOT flow pattern. This is presumptive, as the patient was under general anesthesia and the outflow tract obstruction cannot be confirmed (ie suspected to have resolved at decreased heart rates). Consider reassess in the absence of bradycardia. Regardless, there is mild left atrial dilation for this body size, indicating the risk of spontaneous CHF and/or a thrombotic event is currently low. That being said, mild LA dilation at such a young age is certainly concerning for progression in the future.

While no medications have been shown to definitively alter long term outcome at this stage of disease, atenolol is often initiated to decrease the outflow obstruction. In cases of solely primary MV dysplasia this can lead to improvement in the degree of obstruction and hypertrophy. Given today's findings it is reasonable to initiate this going forward. That being said, the patient is quite young, and I would not start the medication until 6 months of age if referral is declined.



PATIENT

Tiger Smith

Monitor at home for any respiratory signs or evidence of blood clot events (neurologic change, paralysis, etc.). No obvious indication for activity restriction at this time.

SPECIES

Feline

Anesthetic risk is considered mild. Cardiac protective drug choices (opioid/benzodiazepine premedication, propofol or alfaxalone induction, isoflurane gas) are recommended. Pre-oxygenate for 5-10 minutes prior to induction. Monitor for arrhythmias, hypotension, and hypoxia both intra and post-operatively and intervene as necessary. Mild IV fluid restriction is recommended to avoid fluid overload. **Avoid heart rate stimulating drugs such as atropine unless clinically indicated.**

BREED

DSH

Long term prognosis is guarded given the age of the patient and highly variable nature of asymptomatic feline heart disease. Many cats will remain asymptomatic until mid-life or beyond, while others develop CHF within the first years. Close monitoring for progression to LA dilation in the future will help determine long term prognosis.

SEX

Male

PLAN

Consider referral and/or reassessment without sedation if possible. If declined recheck at 6 months of age to determine if atenolol is warranted (without sedation if possible).

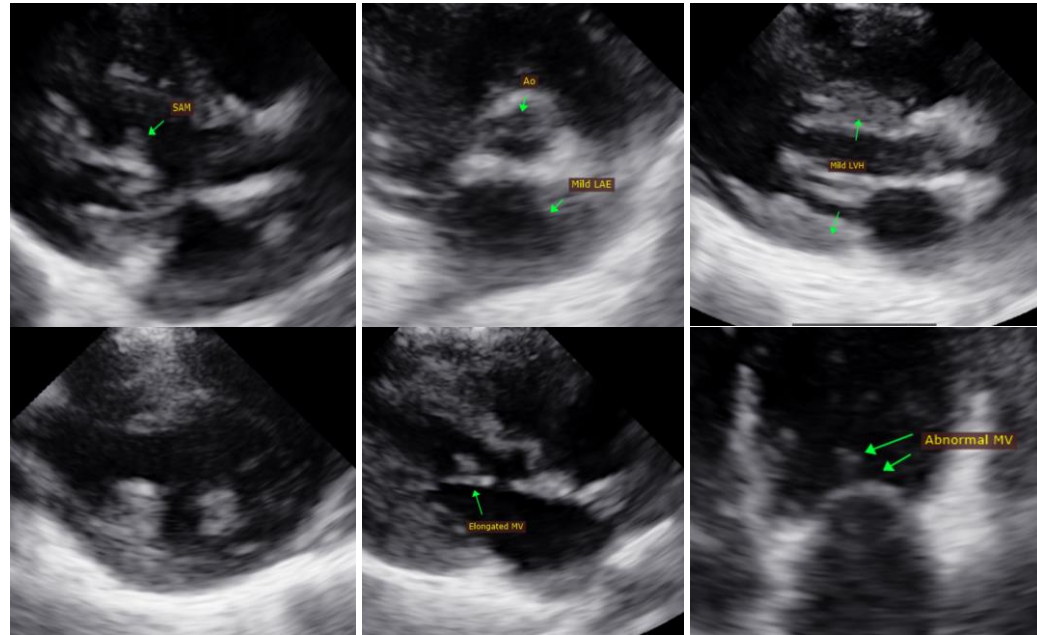
AGE

14 weeks

IMAGES

WEIGHT

6.13lbs



INTERPRETED BY

Maggie Machen Lamy,
DVM, DACVIM
(Cardiology)

IMAGING PERFORMED BY

Amy Mayhew, LVT

HOSPITAL NAME

SVS Imaging MI

REFERRING VET

Oxford Veterinary
Hospital

INVOICE

26607

DATE

9/28/22

The information and recommendations provided are based on the images presented by the referring veterinarian. No evaluation can be communicated regarding pathology that was not visible in the image/video clips provided.

Thank you for this referral. If the clinical or image interpretation does not parallel your findings or if I can be of any further assistance, please contact me.

Maggie Machen Lamy, DVM
Diplomate of the American College of Veterinary Internal Medicine (Cardiology)
info@sonopath.com